

EXPERIMENTAL THERMAL BURNS I

A study of the immediate and delayed histopathological changes of the skin.

RJ Brennan, M.D. and B. Rovatti M.D.

The purpose of this study was to determine the progressive skin changes in thermal burns, with serial biopsies, from the time of burning to the end point of the pathological and healing process.

The available literature is primarily concerned with the terminal effects of burns without particular study of the timing and characteristics of the early histopathological changes. This is reflected in the common classification of burns.

According to the general classifications, burns of first degree involve the epidermis dissecting mostly the outer layers with vesication, hyperemia and slight edema of the dermis. Second-degree burns more seriously involve the dermis with damage to the capillaries, hair follicles and sweat glands, with considerable edema of the dermis. Deep dermal burns are also considered second-degree burns. In third-degree burns the damage involves the entire thickness of the skin.

The process of gradual formation of the eschar has been followed in these experiments examining the gross and microscopic changes step-by-step after establishing a definite procedure to provide:

1. A controlled procedure of burning.
2. A closer examination of the initial damage to the skin structure.
3. The timing of subsequent histopathological changes in the early hours and days following burning.
4. An insight into factors to be corrected and possibly prevented by the early treatment of thermal burns.
5. A uniform method to evaluate the efficacy of early therapeutic measures.

Experimental Findings

Laboratory findings indicate that immediately after the burning, the skin appeared grayish-white with smooth edges. In the first six hours, the color remained the same but the burned area became diffusely edematous with slight elevation of the edges.

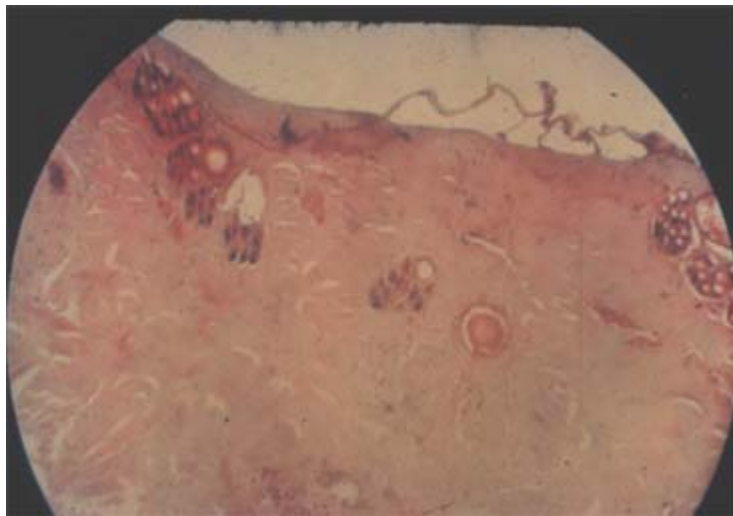
At 24 hours, the burned area was brownish and the surround unburned skin appeared erythematous.

At 48 hours, the burned area was dry and brown and the surrounding skin was markedly congested.

During the following days, the thermally injured skin became dryer and harder until at the tenth day, the edges began to curl and dissect from the underlying tissue. The complete eschar separated on the 13th or 14th day. All tests yielded the same results, the burned areas healed by firm, pearl white, adherent scars by the 29th day.

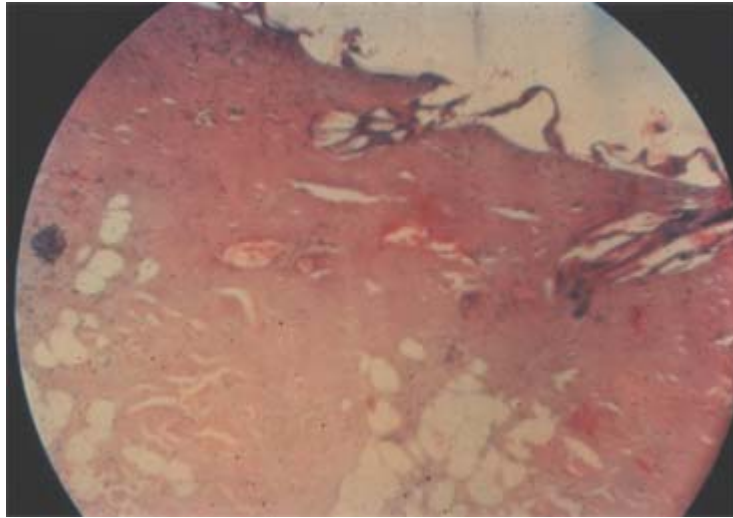
Histopathological changes 30 minutes after thermal burn:

Untreated



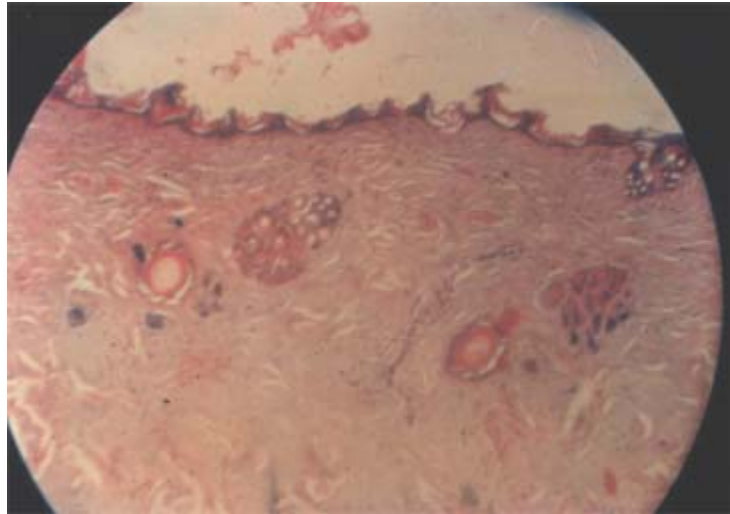
The epidermis is partially dissected forming several vesicles. The upper layers of the dermis were thermally coagulated and show darker staining of the collagen. Present in the capillaries of the deeper layers of the dermis are red thrombi. There are some signs of perivascular inflammatory reaction.

Histopathological changes 1 hour after thermal burn:
Untreated



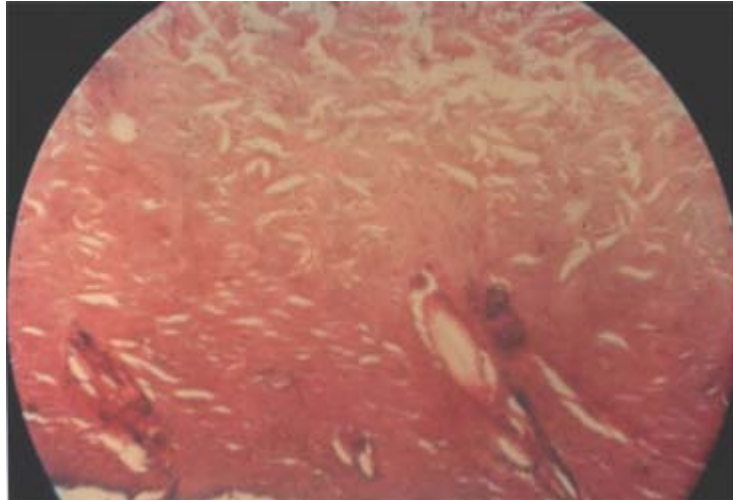
The epidermis is almost entirely dissected from the underlying dermis. The upper layers of the dermis definitely stain darker. In the papillary and the reticular layers of the dermis, there are numerous spaces retaining fluid following thermal coagulation and development of edema. The papillary layer of the dermis shows numerous dilated vessels with sludging of the red cells. Some of the vessels show perietal thrombosis.

Histopathological changes 2 hours after thermal burn:
Untreated



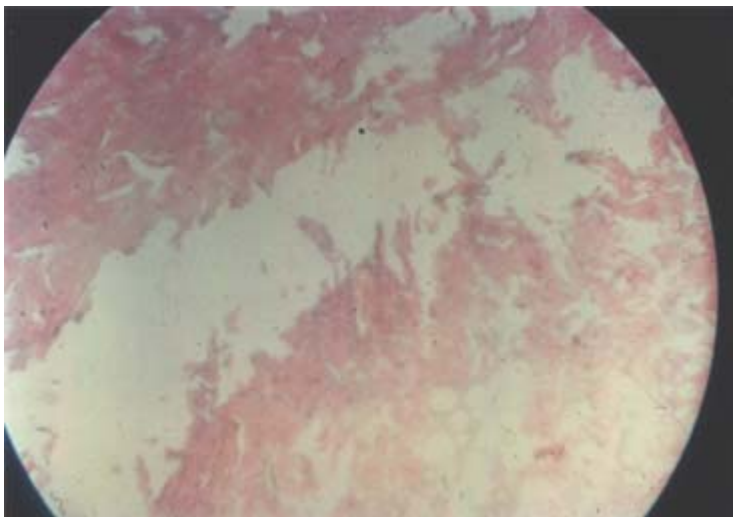
The vesiculation of the upper layers of the epidermis is less evident because the spaces above the stratum germinativum and granulosum are reduced after drying. Numerous round cells have infiltrated the upper layer of the dermis. There is definite thermal damage of the follicular structures. Scattered through the dermis are thrombosed capillaries.

Histopathological changes 6 hours after thermal burn:
Untreated



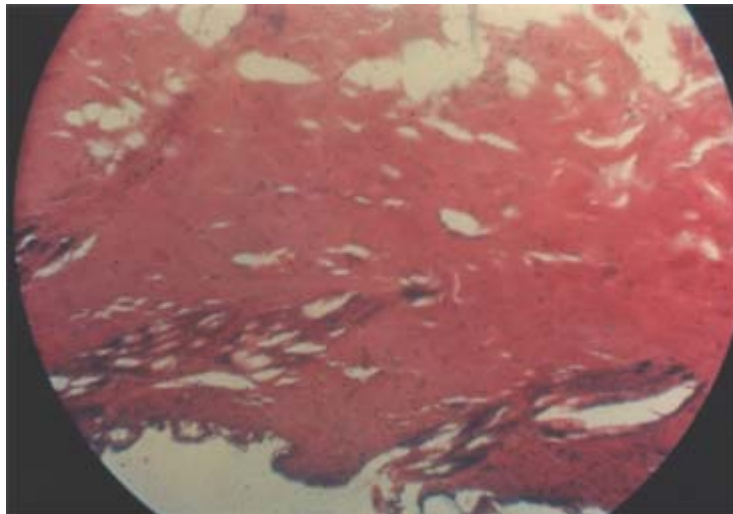
The remainder of the epidermis is very scant. Only a few strips of stratum corium are still present. The stratum germinativum and granulosum show considerable damage due to dehydration. Present within the reticular layer are several larger spaces due to interruption and dissection of the framework of collagen fibers.

Histopathological changes 24 hours after thermal burn:
Untreated



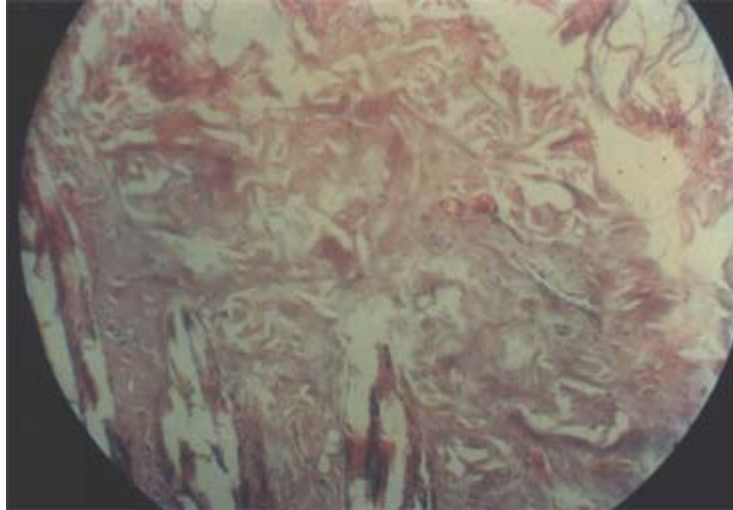The upper layers of the dermis are thermally coagulated and tend to dissect in a large eschar from the deeper layers of the dermis where a marked inflammatory reaction is present. This is the first clear-cut sign of tissue separation. The infiltration of white cells is found only below this demarcation.

Histopathological changes 48 hours after thermal burn:
Untreated



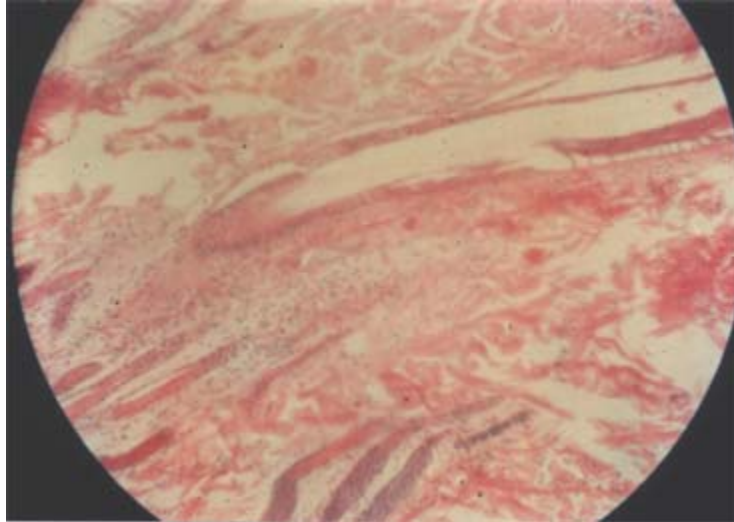
The process of dissection of the upper layer of the dermis is definitely more advanced than at 24 hours. The deeper layers of the dermis show granulation tissue containing numerous thrombosed capillaries surrounded by areas of microscopic debridement and loss of structure.

Histopathological changes 4 days after thermal burn:
Untreated



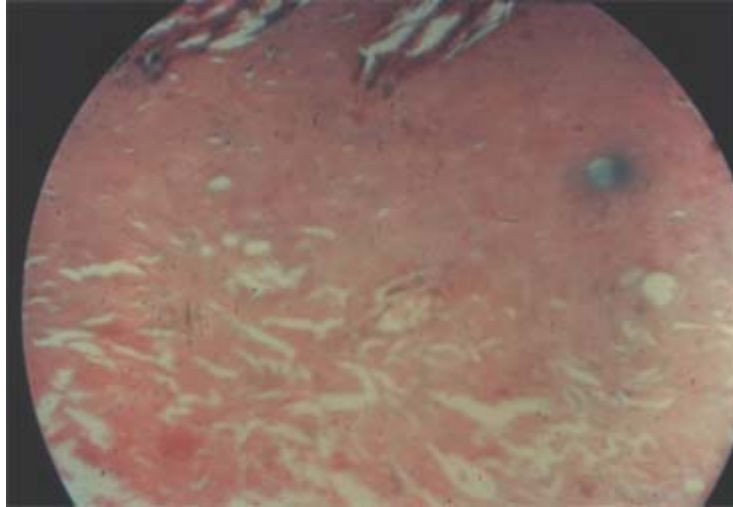
The eschar, formed by the upper layer of the dermis, is entirely separated microscopically. There is a loss of the original structure and the collagen masses show a patchy irregular staining. The epidermis is almost entirely destroyed. There are only a few identifiable areas of the stratum germinativum covered by the debris of dissected stratum corneum.

Histopathological changes 6 days after thermal burn:
Untreated



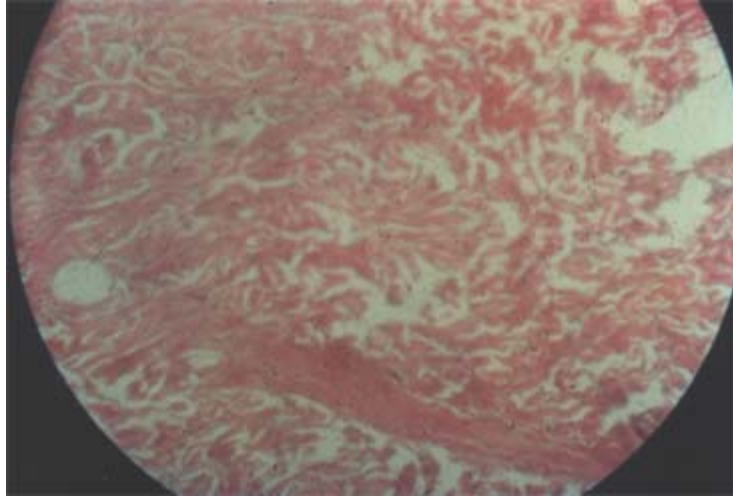
The dermis shows a very loose structure of the reticular layer. There are several vessels exhibiting parietal thrombosis and entirely surrounded by round cell perivascular infiltration. The upper layer of the dermis, which is thermally coagulated, has almost entirely lost its structure and separates from the reticular layer.

Histopathological changes 10 days after thermal burn:
Untreated



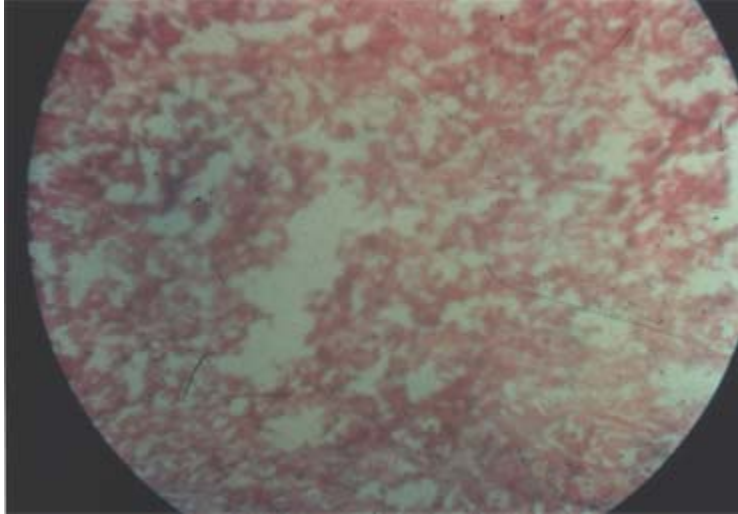
The numerous fragments of amorphous material arising from the thermally damaged dermis are invaded by an abundance of leukocytes. The process of fragmentation takes place in the upper layer of the dermis without significant white cell infiltration. The perivascular reaction is very minimal.

Histopathological changes 12 days after thermal burn:
Untreated



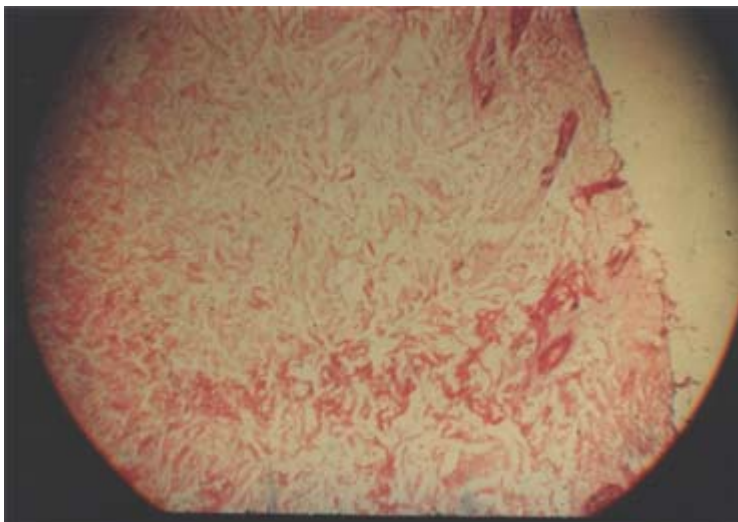
The morphological structure of the upper layer of the dermis is entirely lost. Dissection of the collagen fibers and vacuolization are still evident but the picture is partly one of dry necrosis of the eschar and partly one of microscopic colliquation or softening of the underlying reticularis.

Histopathological changes 14 days after thermal burn:
Untreated



All fields of dermal tissue show an arborescent structure of dissociated collagen branches undergoing partial autolysis. In some areas there are still present some nests of white cells. The process appears to be due mainly to enzymatic proteolysis.

Histopathological changes 18 days after thermal burn:
Untreated



The image of arborization of the dermal tissue has markedly changed, due to a process of small fragmentation in which the tissue particles have lost their structure and stainability and are undergoing a process of debridement.

OBSERVATIONS

Untreated

The thickness of the skin used in the experiments averaged 3 mm. The epidermis measures 400 microns of which 150 microns is stratum disjunctum and stratum corneum and 250 microns is stratum lucidum, granulosum and germinativum.

The serial observation of the histopathological changes of the skin following thermal burns show immediate coagulation followed shortly by gross edema. The findings in the dermis suggest that capillary effusion tends to thicken and separate the collagen fibers. During the first 24 hours, the injured skin tends to dehydrate as evidenced by the darker staining of upper areas. Capillary thrombosis extends rapidly throughout the dermis. Between 24 and 48 hours there is definite microscopic evidence of separation of the injured tissue from the deeper dermis. There we find increased numbers of round cells and polymorphonuclear leukocytes in the perivascular tissue. In the separated epidermis and dermis the white cell infiltration was practically absent. According to our previous experiments, the line of demarcation is the port of entry of bacterial invasion.

Beginning at the 4th day and continuing through the 10th day there is fragmentation of the thermally coagulated tissues and at this time the eschar starts to separate grossly and there is microscopic evidence of granulation and infiltration of the underlying tissue which sequesters the eschar.

CONCLUSION

Untreated

Gross and microscopic observations in this experiment showed that the eschar forms and separates microscopically in 24 to 48 hours after thermal burns. The eschar separates grossly in 10 to 14 days.

There are some immediate coagulation changes after thermal burns. However, the microscopic separation of the eschar does not occur until 24 to 48 hours.

These experimental studies, showing this clear-cut separation and demarcation, suggest that early treatment should be directed toward the prevention of the changes, which produce the formation of the eschar within the first 24 hours.

EXPERIMENTAL THERMAL BURNS I

A comparative study of the immediate and delayed histopathological changes of the skin in treated and untreated thermal burns.

R.J. Brennan, MD and B. Rovatti, MD

It is well known that approximately one week after a thermal burn, an eschar begins to separate. However, there is little if any description in the literature of the successive microscopic changes as they develop during the first 48 hours. We attribute this to the feeling that the extent of the damage is determined at the time of injury. Our study of the timing of subsequent histopathological changes in the early hours and days following thermal burns suggested that early medical treatment could possibly modify some of these early changes and prevent some of the later changes.

In our previous experiments on untreated thermal burns, gross and microscopic observations showed that the eschar forms and separates microscopically in 24 to 48 hours and the eschar separates grossly in 10 to 14 days. We, therefore, undertook this comparative study of the effectiveness of various methods of early medical treatment using our previously established controlled procedure of burning.

Experimental Procedure

In the Laboratory we divided the tests into four groups. The skin used was epilated on both sides over a 4 x 4 cm area. Each skin was burned for two seconds on both epilated areas using the previously described steel plate of 43 mm diameter with our controlled heating procedure. One area of the skin was treated while the other served as the control and was thus available for gross and microscopic comparison.

Experimental Findings

Group I – Treated with Alo-Crème-Ointment

Six hours after burning, the treated area was grayish-white and edematous. At 24 hours, the treated area was more pliable than the untreated area of the same animal. There was definitely less erythema around the treated burned area than there was around the untreated control area. At 48 hours the untreated area was brown and definitely dryer than the burned area treated with Alo-Crème-Ointment. During the following days, the treated area remained soft and pliable while the untreated area became harder and dryer. Between the 7th and 15th days, there was slight and continuous superficial debridement of the treated area without gross formation of an eschar while after two weeks the untreated area showed a large eschar, which gradually separated from the underlying tissue. The Alo-Crème treated lesions healed in two weeks without gross evidence of scarring. By the end of the fourth week, the untreated area healed with a firm pearly-white scar.

Group II – Treated with Alo-Crème-Ointment containing 5% cystine

During the first week the treated areas were similar to the treated areas of Group I. In the second week the debridement appeared to be greater in Group II than in Group I. The healing process similarly took place without the formation of a gross eschar and by the third week the treated areas gradually became softer, more pliable and less edematous.

Group III – Treated with 1% trinitrophenol butylaminobenzoate ointment

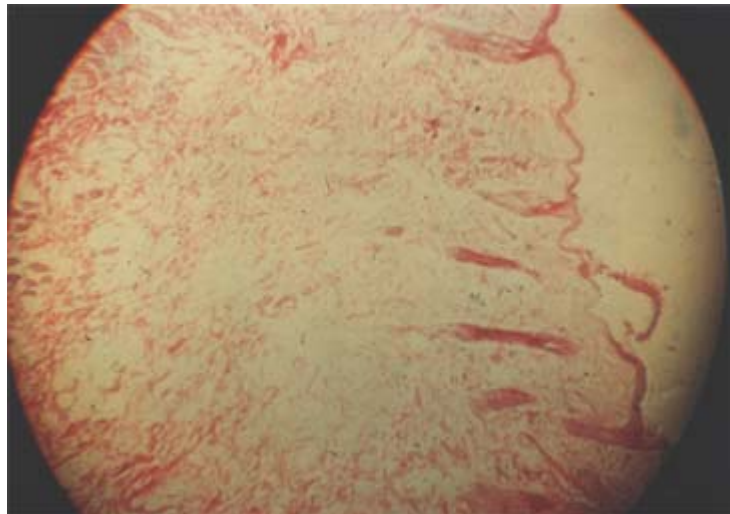
At 24 hours the treated areas were grossly similar to those of Groups I and II. During the next 48 hours the treated area became soft and edematous while the surrounding skin became markedly congested. At the end of the first week the periphery of the treated area showed multiple petechial hemorrhages while the center became white and gelatinous.

Group IV – Treated with petrolatum and gauze

During the first three days there was a gradual development of congestion, edema and focal hemorrhages. By the end of the first week the treated area had gradually changed from grayish-white to brown. At this time there were several small abscesses in the skin. During the second week of purulent eschar separated leaving granulation tissue. By the end of the fourth week the treated area healed by the formation of a firm pearly-white scar similar to the untreated area of the same skin sample.

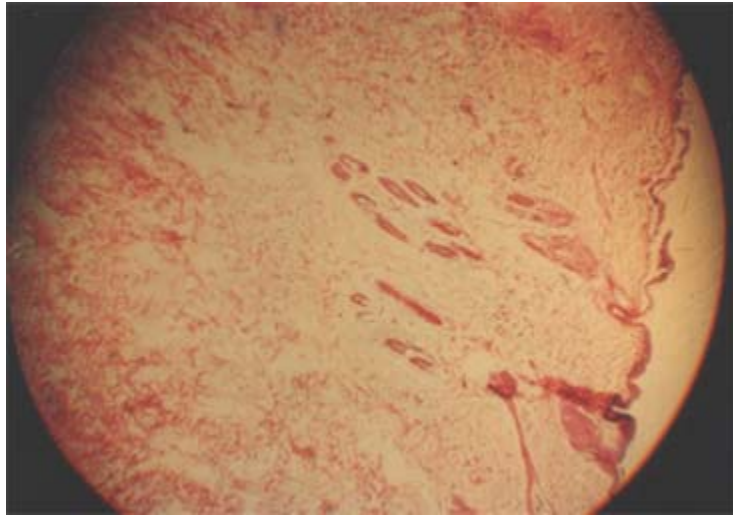
GROUP I

Histopathological changes 30 minutes after thermal burn



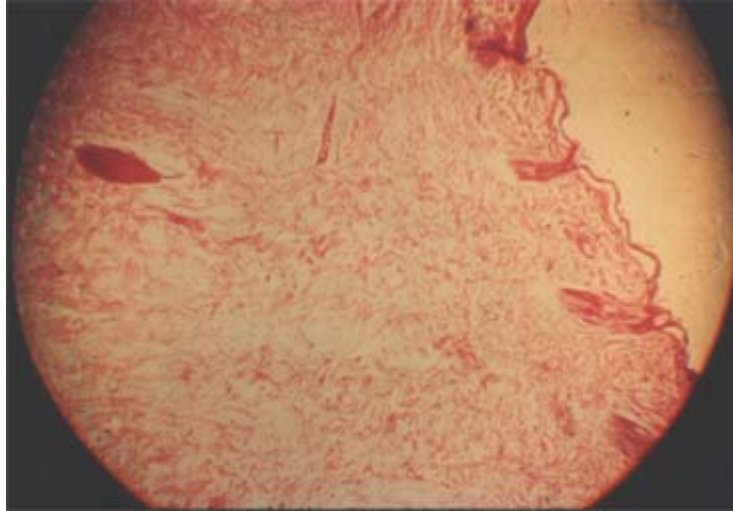
The epidermis is almost entirely missing and where it is still present it forms several vesicles. The upper layers of the dermis do not stain as darkly as in the control. There is no definite perivascular reaction. There are no thrombi present in the capillaries of the deep dermis.

GROUP I
Histopathological changes 1 hour after thermal burn



There is diffuse edema with marked capillary congestion in the reticular layer of the dermis. There is no evidence of thrombosis. The perivascular reaction is minimal and present only in a few isolated areas of the deep dermis.

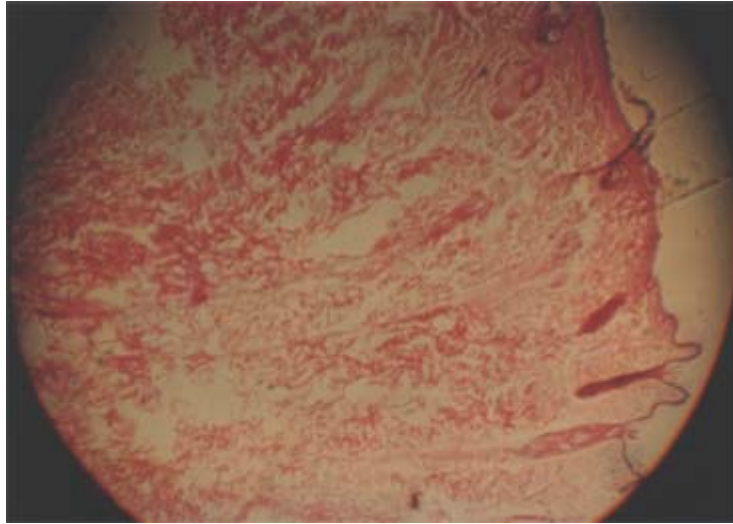
GROUP I
Histopathological changes 2 hours after thermal burn



The epidermis is almost entirely dehydrated and soiling. The upper layer of the dermis shows slight thermal coagulation. In numerous areas of the deep dermis the capillaries are congested and there is some sludging of the red cells without thrombosis.

GROUP I

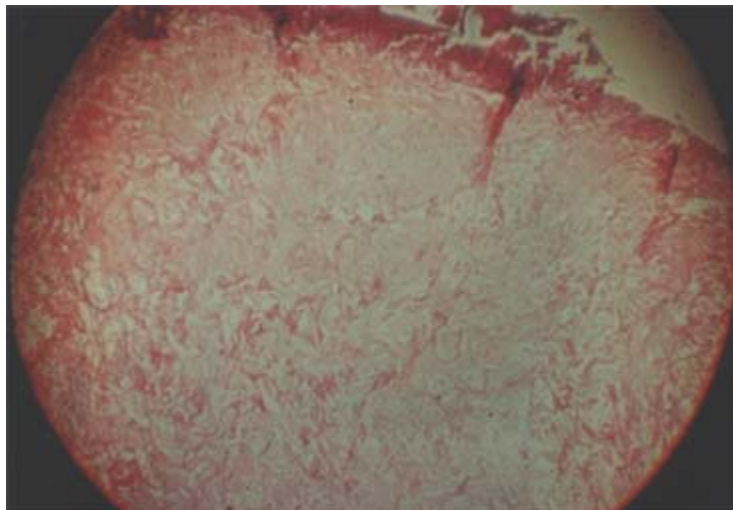
Histopathological changes 6 hours after thermal burn



The epidermis is almost entirely missing. The upper layers of the dermis do not show any evidence of dehydration as in the controls. The framework of the collagen fibers shows evidence of some edema. Diffuse capillary congestion, slight round cell infiltration, and fibroblastic activity are present.

GROUP I

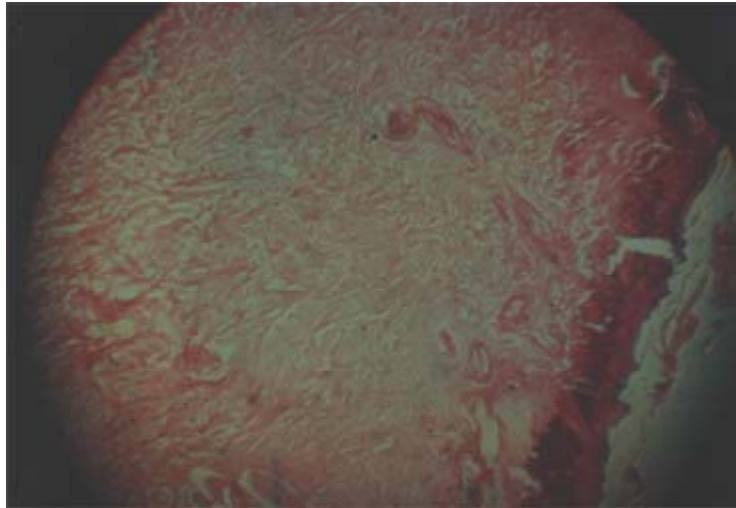
Histopathological changes 24 hours after thermal burn



There is very little evidence of thermal necrosis of the upper dermis. There is no indication that the upper layers of the dermis will dissect from the deeper layers forming an eschar as in the controls. The round cell infiltration is more abundant and mostly perivascular.

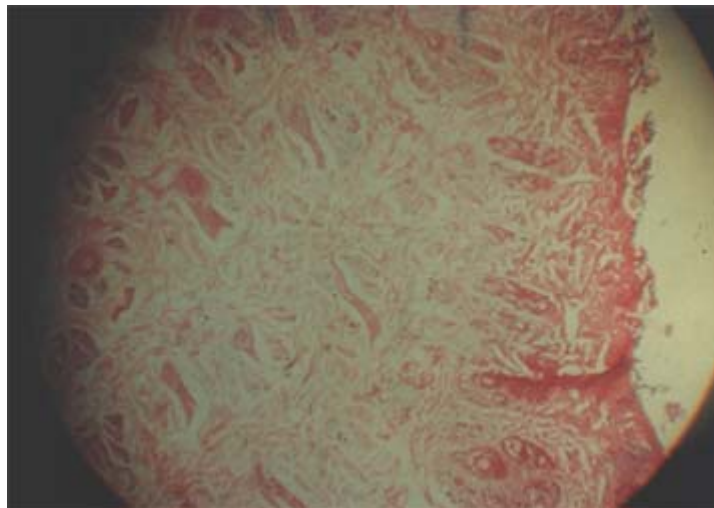
GROUP I

Histopathological changes 48 hours after thermal burn



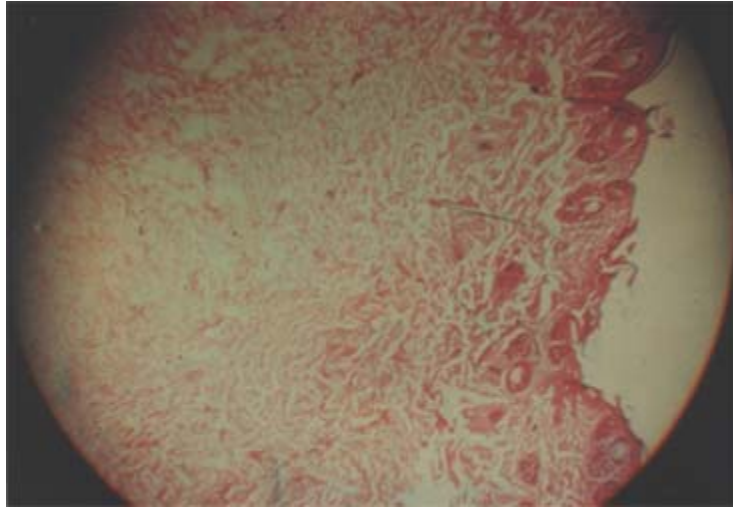
The superficial layer of the dermis is slightly debriding and it shows some infiltration with polymorphonuclear leucocytes. There is diffuse congestion and edema. There are no areas of necrosis found within the dermis.

GROUP I
Histopathological changes 4 days after thermal burn



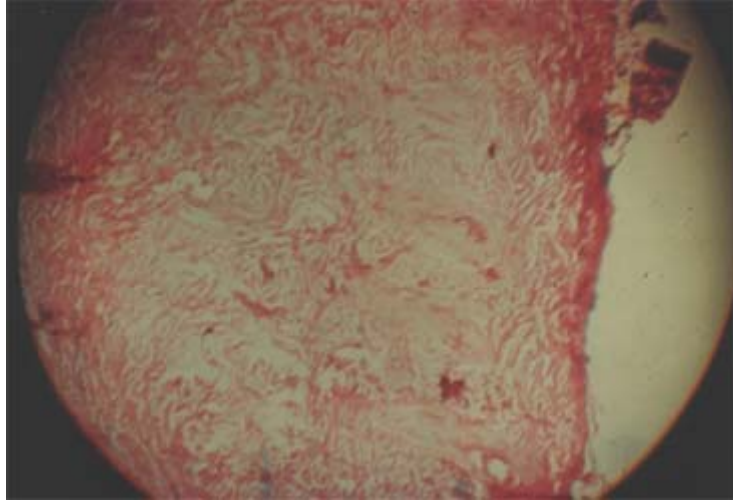
There is microscopic evidence of superficial debridement of the upper dermis. The texture of the deep dermis is well preserved and the collagen fibers appear practically normal. The capillaries are free from thrombi. A few tiny perivascular hemorrhages are present in the deep dermis.

GROUP I
Histopathological changes 6 days after thermal burn



The epidermis shows regeneration from the basal layer. Some edema is still present in the dermis and there are several clusters of round cells and fibroblasts. There is no evidence of thrombosis or necrotic dissection in the dermis.

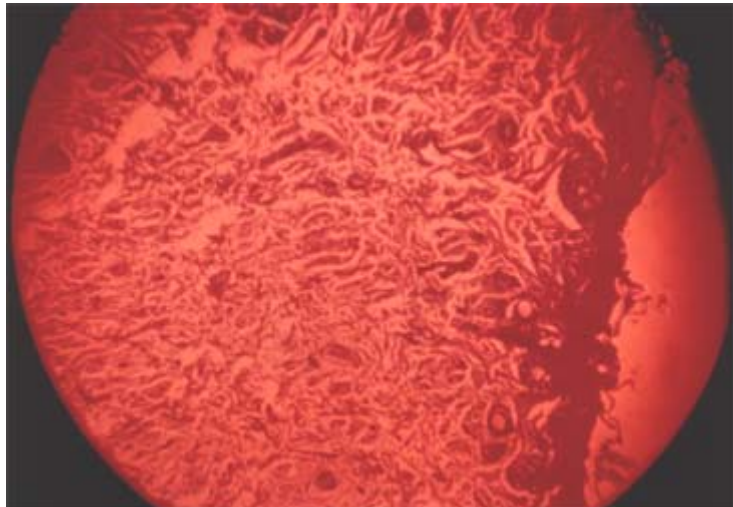
GROUP I
Histopathological changes 10 days after thermal burn



Epithelial hyperplasia is evident in several areas. The thermally injured dermis still shows some superficial debridement. The fibroblastic activity is increased in all layers of the dermis. There are numerous vessels exhibiting round cell perivascular infiltration.

GROUP I

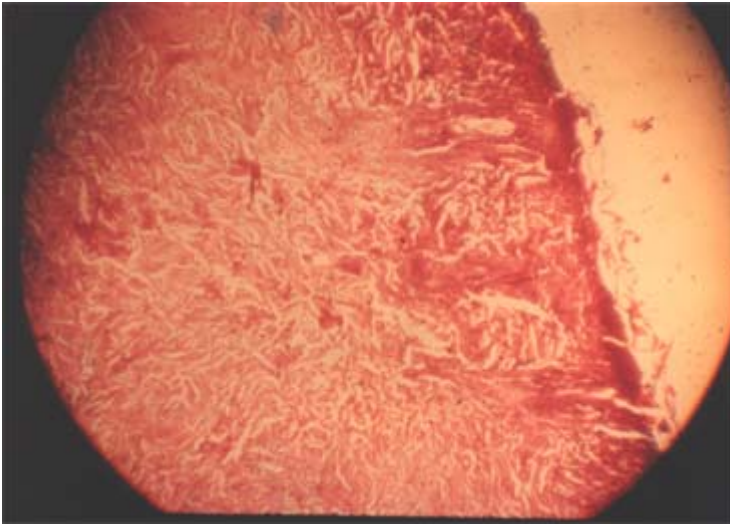
Histopathological changes 12 days after thermal burn



There is active epithelial regeneration and there is still some superficial debridement of the upper layer of the dermis. A few small hemorrhages and diffuse fibroblastic activity are present in the deep dermis.

GROUP I

Histopathological changes 14 days after thermal burn



The epidermis is actively regenerating with hyperplasia of the basal layers and several epithelial pearls. The texture of the collagen fibers of the dermis is more dense than normal and there are numerous scattered fibroblasts. There are no areas of necrosis or enzymatic proteolysis evident.

GROUP I

Histopathological changes 18 days after thermal burn

Epithelial regeneration continues. Hyperplasia of collagen is present in the upper dermis without definite evidence of scarring. There are many fibroblasts in the deep dermis and several clusters of round cells surround the capillaries.

GROUP II

The microscopic findings in these skins treated with Alo-Crème-Ointment containing 5% cystine did not show appreciable difference from those of Group I in the first 48 hours. However, after four days there was a more marked hyperplasia of the basal layer of the epidermis. During the second and third weeks there was intensive fibroblastic activity, moderate congestion and diffuse collagen hyperplasia in the dermis.

GROUP III

Histopathological changes

Marked edema, severe congestion, and isolated capillary thrombosis developed during the first six hours. At 48 hours the upper dermis showed dissection from the deeper dermis. At four days there were many hemorrhages in the dermis. Capillary congestion and perivascular polymorphonuclear infiltration increased between the fourth and tenth days. At this time there was massive debridement of the superficial layers of the dermis which was infiltrated with polymorphonuclear leucocytes while there was some evidence of fibroblastic activity in the deeper layers of the dermis.

GROUP IV

Histopathological changes

The microscopic appearance of the areas treated with petrolatum and gauze was similar to that of Groups I and II in the first two hours except that there was more dehydration and isolated capillary thrombi at two hours. At six hours the dermis showed leucocytic infiltration, which became very abundant at 24 hours. At this time there were many capillary thrombi and the upper layer of the dermis showed massive dark stained areas which were debriding. At 48 hours, the microscopic demarcation of the eschar was complete. After one week there was intensive fibroblastic activity underlying the zone of demarcation. At the end of the second week the entire eschar was shredded and debriding in large pieces which were densely infiltrated with polymorphonuclear leucocytes.

During the third and fourth weeks there was marked collagen hyperplastic, fibroblastic activity and scarring with very little regeneration of the epidermis. There was little difference between this group and the controls.

CONCLUSION

Gross and microscopic observations in these experiments showed that in deep dermal burns and eschar forms and separates microscopically in 24 to 48 hours and grossly the eschar separates in 10 to 14 days if the skin is not treated with ointment after burning.

GROUP I – Treated with Alo-Crème-Ointment

The skin burned and treated with Alo-Crème-Ointment remained pliable and soft during the first week with slight and continuous superficial debridement of the upper dermis and without gross or microscopic separation of the eschar. These lesions healed in two weeks without gross evidence of scarring.

Group II – Treated with Alo-Crème-Ointment containing cystine

During the second week, identical burns treated with Alo-Ointment containing 5% cystine, showed more superficial debridement than observed in animals of Group I. There was no gross or microscopic separation of an eschar and no gross scarring occurred. There was little or no difference between this group, where 5% cystine was added, and Group I.

Group III – Treated with 1% trinitrophenol butylaminobenzoate ointment.

The appearance of the skin treated with this ointment was comparable during the first 24 hours to that observed in Groups I and II. Subsequently these lesions became grossly and microscopically hemorrhagic and the separation of an eschar was evident microscopically at 48 hours.

Group IV – Treated with petroleum and gauze

During the first three days there was a gradual development of congestion, edema, and focal hemorrhages of the skin area in the burns treated with petroleum and gauze. Microscopically an eschar did develop and separate during the first 48 hours. By the end of the first week there were numerous hemorrhages and several small abscesses. At the end of the second week the entire dermis was debriding in large masses and the lesion healed by scarring during the third and fourth weeks.